

1. Dislocation and osteotomy of femoral neck.

2. Reaming of medullary cavity.

3. Application of curved rasps of medial cavity to 10° 15° antetorsion.

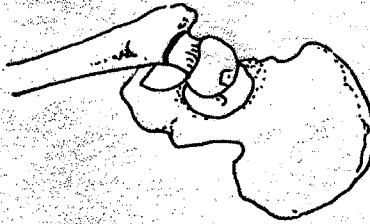
4. Final reaming of medial cavity up to total cancellous bone take off.

5. Excavation using form rasps with gradually increasing sizes.

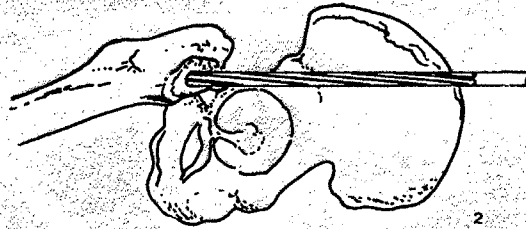
6. Deeping the rasps 3 mm under the resection level.

7. Seating the test prosthesis with the hands.

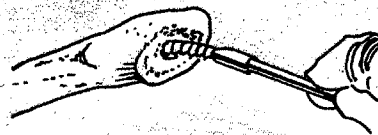
8. Rectifying the calcar.




1



2



3



4



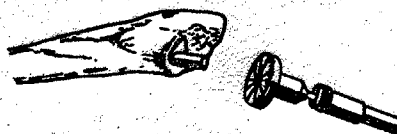
5



6



7



8

1. Luxar. Osteotomia do colo femoral.

2. Fresagem do canal.

3. Com o raspador curvo, preparar o osso medial mantendo aproximadamente 10° a 15° de anteversão.

4. Raspagem do osso medial e retirada do osso esponjoso.

5. Introdução dos raspadores gradualmente até o tamanho da prótese a ser usada.

6. Aprofundar o raspador aproximadamente 3 mm além do nível de ressecção.

7. Colocar a prótese de teste com a mão sem forçar.

8. Retífica do calcar.